

Sustained IOP reductions seen with canaloplasty, new study suggests

Sean Henahan

CANALOPLASTY provides sustained reductions in IOP in primary open-angle glaucoma patients, with far fewer complications than trabeculectomy, a new study suggests.

Researchers reported the three-year results of canaloplasty in 97 eyes of patients, along with a comparison group of 120 eyes that underwent viscocanalostomy. Canaloplasty produced a mean lowering of IOP from 27 to 14 mmHg, a mean drop of 48 per cent (Table 1). The investigators also report a reduction in adjunctive medications used (Table 2). Some 96 per cent of canaloplasty patients achieved an IOP of 21 mmHg or lower, 55 per cent without additional drops. A comparison with patients who underwent viscocanalostomy showed statistically significant differences in favour of the canaloplasty group in the number of patients achieving a postoperative IOP of 17 mmHg or less, and in medication requirements (Table 3).

"We conducted this study in primary open-angle glaucoma patients because we felt it was important that we establish whether it works in normal open-angle glaucoma before making recommendations for other cases. Viscoanalostomy and canaloplasty are both excellent procedures. We wanted to see if we could get better results with canaloplasty, meaning greater lowering of intraocular tension, and prevention of the failure of viscocanalostomy from ostial closure, the one problem that does occur with time in that procedure. We wanted to establish a benchmark for future studies," said Clive Peckar MSc(Oxford) FRCS FRCSed FRCOphth, consultant ophthalmic surgeon, Warrington, UK.

Both canaloplasty and viscocanalostomy have similar low complication rates (Table 4). The only marked difference in complications was an increased incidence of transient hyphaema postoperatively in the canaloplasty patients.

"We are not overly concerned about the hyphaema. This is a physiological effect of holding the canal wide open and putting tension on the meshwork," Dr Peckar commented.

There are cases where the catheter will not pass in canaloplasty. He noted that even though catheters have been improved, even with latest designs and experience, there are a proportion of patients who can't pass the catheter for anatomical reasons. Those patients still experience the benefits of viscocanalostomy.

None of the patients developed visual loss or cataract during the duration of the study.

The low rate of complications with these procedures compares favourably against MMC-trabeculectomy, for which published studies report endophthalmitis rates

approaching 3.0 per cent, as well as other serious complications including hypotony maculopathy¹. Moreover, a UK national study of trabeculectomy² reported early complications in 47 per cent of cases and late complications in 43 per cent. The most frequent early complications, of trabeculectomy, were hyphaema (25 per cent), shallow anterior chamber (24 per cent), hypotony (24 per cent), wound leak (18 per cent) and choroidal detachment (14 per cent). The most frequent late complications reported for trabeculectomy were cataract in 20 per cent and visual loss in 19 per cent.

New age of Schlemm's canal surgery

"Up until the end of the last century, fistularising surgery, most recently trabeculectomy, was the operation of choice for the majority of ophthalmologists worldwide. With viscocanalostomy we entered into the new age of Schlemm's canal surgery, allowing our patients to have comfortable 'bleb free' eyes without the devastating complications of gross hypotony and endophthalmitis, and allowing their surgeons to sleep better at night. With canaloplasty we have advanced one step nearer to the goal of 'bleb-independent, safe glaucoma surgery,'" Dr Peckar told *EuroTimes*.

The data thus far suggest that the benefits of canaloplasty persist over time, with no diminution of effect. There is no change in appearance of the tension sutures over time. Indeed, there are anecdotal reports where pressure continues to drop as the months go by, he noted.

Dr Peckar explained that a potential limitation of current medical treatment with prostaglandin analogues is that these agents work by increasing uveo-scleral outflow, bypassing Schlemm's canal and the collector channels and that in time this may contribute to Collector Channel Collapse. The advantage of these newer procedures is that they re-establish flow through Schlemm's canal, re-establishing the normal physiological state within the eye, he said.

Surgical technique

"With viscocanalostomy we mark an area on the sclera, usually at 12:00 position, about 5.0mm from the limbus. We make a parabolic opening through the sclera, and produce a superficial sclerectomy flap that is designed to be watertight. Inside that we make a secondary sclerectomy flap, and cut down until we can just see the choroid. We cross the scleral spur to Schlemm's canal, de-roof

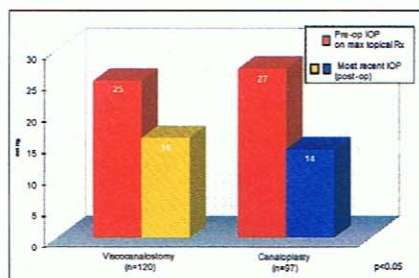


Table 1: Mean Intraocular Pressures: Viscoanalostomy & Canaloplasty

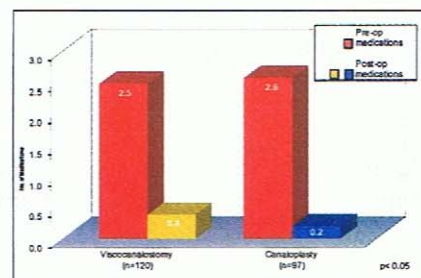


Table 2: Mean Medications: Viscoanalostomy & Canaloplasty

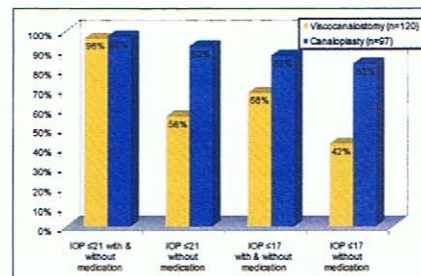


Table 3: Success: Viscoanalostomy and Canaloplasty

the canal, and create a 'Descemet's window'. We then remove the block of sclera, creating a scleral lake. Next we dilate the two ends of Schlemm's canal with viscoelastic, producing direct access into the canal and the collector channels. We then suture the flap, having achieved internal bleb-independent surgery. Postoperative care includes topical steroids, anti-prostaglandins, and antibiotics.

The advantage of this approach is that you produce a deep sclerotomy with a Descemet's window. This prevents gross hypotony. You have no direct fistula through the sclera, and therefore no flat anterior chambers or choroidal detachments. As these procedures produce internal drainage through Schlemm's canal, we have no problem with late bleb failure or infection, since there is no bleb.

Canaloplasty evolved from viscocanalostomy, a procedure developed by pioneering surgeon Prof Robert Stegmann. Dr Jack Kearney worked with iScience to develop a 250µ microcatheter to viscodilate the whole of Schlemm's canal. Dr Stegmann then took the new technique a step further by using the microcatheter to place a 360° circumferential tension suture within Schlemm's canal to hold the canal and ostia open and place the canal under tension.

During catheterisation of the canal Collector Channel Microangiography (CCMA) may be carried out through the microcatheter, in order to document the

distribution and patency of the collector channel network, using trypan blue, which illustrates the high concentration of collector channel vessels draining the superior nasal quadrant of Schlemm's canal.

The current study, conducted by Clive Peckar and Norbert Körber MD, appears in the journal *Spektrum der Augenheilkunde*³.

clivepeckar@yahoo.co.uk

References:

- Wishart PK. Trabeculectomy is not the best surgical option for glaucoma. *Eye* 2008; 22: 603-606
- Edmunds B, Thompson JR, Salmon JF, Wormald RP. The National Survey of Trabeculectomy. III. Early and late complications. *Eye* 2002; 16: 297-303.
- Peckar C O, Körber N. Canaloplasty for open angle glaucoma: a three years critical evaluation and comparison with viscocanalostomy *Spektrum der Augenheilkunde* (2008) 22/4: 240-246.

Complications	Viscoanalostomy n=121	Canaloplasty n=97
Hyphaema (transient)	2 (1.7%)	10 (10%)
Descemet's split > PI	2 (1.7%)	1 (1%)
Converted to trabeculectomy	0	0
Choroidal detachment	1 (0.8%)	0
Pressure spike (1 day post-op >30mmHg)	0	1 (1%)
Laser Trabeculectomy (post-op)	3 (2.5%)	0
Resuturing of sclerectomy/conjunctiva	0	2 (2%)
Bleb revision (post-op)	1 (0.8%)	0
Flat Anterior Chamber	0	0
Failed: Surgical Revision	2 (1.7%)	0
Trabeculectomy	0	0
Ahmed Valve™	0	1 (1%)
Prolene Tension Suture:		
No Suture: microcatheter did not pass 360°	-	9 (9%)
Microcatheter Suprachoroidal	-	1 (1%)
Sub-Descemet's Healed	-	3 (3%)
Suture 'cheese-wired' post-op	-	1 (1%)

Table 4: Complications: Viscoanalostomy & Canaloplasty