

JOURNAL OF
**CATARACT &
REFRACTIVE SURGERY**

**Canaloplasty: Circumferential Viscodilation
and Tensioning of Schlemm Canal Using a Flexible
Microcatheter for the Treatment of Open-Angle
Glaucoma in Adults**

Two-Year Interim Clinical Study Results

Richard A. Lewis, MD, Kurt von Wolff, MD, Manfred Tetz, MD, Norbert Koerber, MD,
John R. Kearney, MD, Bradford J. Shingleton, MD, Thomas W. Samuelson, MD

Canaloplasty: Circumferential viscodilation and tensioning of Schlemm canal using a flexible microcatheter for the treatment of open-angle glaucoma in adults

Two-year interim clinical study results

Richard A. Lewis, MD, Kurt von Wolff, MD, Manfred Tetz, MD, Norbert Koerber, MD, John R. Kearney, MD, Bradford J. Shingleton, MD, Thomas W. Samuelson, MD

PURPOSE: To evaluate 2-year postsurgical safety and efficacy of canaloplasty (circumferential viscodilation and tensioning of the inner wall of Schlemm canal) to treat open-angle glaucoma (OAG).

SETTING: Multicenter surgical sites.

METHODS: This international prospective study comprised adult OAG patients having glaucoma surgery or combined glaucoma–cataract surgery. Qualifying preoperative intraocular pressure (IOP) was at least 16 mm Hg and historical IOP, at least 21 mm Hg. The full circumference of the canal was viscodilated and a trabecular tensioning suture placed with a microcatheter. Primary outcome measures included IOP and glaucoma medication use.

RESULTS: At 24 months, all 127 eyes (127 patients) had a mean IOP of 16.0 mm Hg \pm 4.2 (SD) and mean glaucoma medication use of 0.5 \pm 0.8 (baseline values 23.6 \pm 4.8 mm Hg and 1.9 \pm 0.8 medications). Eyes with canaloplasty alone had a mean IOP of 16.3 \pm 3.7 mm Hg and 0.6 \pm 0.8 medications (baseline values 23.2 \pm 4.0 mm Hg and 2.0 \pm 0.8 medications). Eyes with combined glaucoma–cataract surgery had a mean IOP of 13.4 \pm 4.0 mm Hg and 0.2 \pm 0.4 medications (baseline values 23.1 \pm 5.5 mm Hg and 1.7 \pm 1.0 medications). The IOP and medication use results at all time points were statistically significant versus baseline ($P < .001$). The late postoperative follow-up identified 3 patients with elevated IOP. No other serious ocular or nonocular complications were reported.

CONCLUSION: Canaloplasty was safe and effective in reducing IOP in adult patients with OAG.

J Cataract Refract Surg 2009; 35:814–824 © 2009 ASCRS and ESCRS

Open-angle glaucoma (OAG) is a disease in which the physician often observes a gradual loss of vision in a patient on medical therapy until surgical intervention is necessary to preserve the remaining vision. Traditionally, a surgical procedure, trabeculectomy, is performed to penetrate the anterior chamber and shunt the aqueous humor to a subconjunctival bleb to reduce intraocular pressure (IOP). Although trabeculectomy can achieve a large reduction in IOP and successfully preserve vision in most patients,^{1,2} the acute postsurgical complications of the procedure are frequent and may in themselves cause loss of vision.^{3–8} In addition, the resulting subconjunctival

bleb poses an ongoing risk for infection or hypotony and may require treatment or surgical revision to maintain function.^{9–14}

Surgical methods to restore the natural aqueous outflow system and the trabeculocanalicular outflow pathway to treat OAG have long been of interest.^{15–17} Such methods would obviate the need for a subconjunctival bleb and might reduce the complications associated with penetration of the intraocular space and shunting aqueous to nonphysiologic routes. However, such methods typically treat only a segment of the distal outflow pathway and lower IOP less than trabeculectomy and there are difficulties with surgical consistency.^{18–22}

Recent advances in technology have allowed glaucoma surgeons to use a flexible microcatheter to access the lumen of Schlemm canal along its entire length.²³ The treatment approach led to the development of a nonpenetrating surgical procedure called canaloplasty, which involves catheterization and viscodilation of the entire length of the canal. In addition, a suture is placed within the canal to tension the inner wall and the associated trabecular meshwork with the intention of restoring natural trabeculocanalicular aqueous outflow.

Previously, we reported the 1-year interim results in a multicenter prospective clinical study of canaloplasty in adults with OAG.^{24,25} The 1-year interim results showed a significant reduction in IOP and glaucoma medication use with few surgical complications. This 2-year interim analysis is intended to address, in part, the longevity of the treatment's efficacy and safety, an important consideration in the treatment of OAG. Anterior segment imaging continues to be a component of the study to relate postsurgical anterior segment morphology with IOP efficacy.

PATIENTS AND METHODS

Design

This is a 2-year interim report of an ongoing international multicenter prospective open-label surgical study of canaloplasty at 14 clinical sites in the United States and Germany, with 16 surgeon investigators. The study was performed in accordance with the principles set forth in the Declaration of Helsinki, the Regulations and Guidelines of the U.S. Food and Drug Administration, International Organization for Standardization ISO 14155-1, and the International Conference on Harmonisation: Good Clinical Practices. The study was designed to evaluate the safety and efficacy of the canaloplasty procedure to reduce IOP in nonpenetrating surgery for OAG. The protocol was approved for each study

site by the appropriate institutional review board or ethics committee (IRB/EC), and all patients (or their legal representative) read, signed, and dated an IRB/EC-approved consent form before having a screening examination and participating in the study. As a result of the encouraging results in the initial study with a 12-month follow-up, all enrollees were requested to complete an additional IRB/EC-approved patient consent for extended follow-up at 6-month intervals for up to 5 years. Additional details of the study methods were described with the 1-year interim results.^{24,25}

All enrollees had a single complete baseline ophthalmic examination including history of glaucoma, medication use, IOP, best corrected visual acuity (BCVA), gonioscopy, and slitlamp and fundus evaluation. Postoperative follow-up examinations were at 1 day, 1 week, and 1, 3, 6, 12, 18, and 24 months at minimum. Postoperative evaluations included IOP measurements, BCVA, slitlamp examination, gonioscopy, ophthalmic medication reporting, and adverse event reporting. The preoperative and postoperative medication regimens were investigator specific and recorded at each follow-up visit.

High-resolution ultrasound biomicroscope (UBM) images were obtained using a system designed for intraoperative and office-based anterior segment imaging (iUltrasound, iScience Interventional) to characterize anterior angle morphology before and after surgery. At least 1 postoperative UBM examination was scheduled for each patient during the follow-up period to evaluate the role of anterior angle morphology on surgical outcome.

Patient Inclusion and Exclusion Criteria

The study protocol was designed to allow flexibility in patient selection and treatment options to reflect each investigator's current practice of glaucoma surgery. Specifically, phacoemulsification with posterior chamber intraocular lens (IOL) implantation in combination with canaloplasty and previous surgeries that would not interfere with complete circumferential catheterization of Schlemm canal were allowed. The data analysis was segregated to evaluate results in different subgroups of patients and treatment options. Study monitors verified all patient enrollment and examination case report forms against the patient medical records during the course of the study. Eyes that did not meet enrollment criteria during this verification were excluded from this analysis but were continued to be examined by the respective investigators for postoperative complications.

All patients were 18 years or older at the time of enrollment, able to understand and provide informed consent, and scheduled for glaucoma surgery or combined cataract and glaucoma surgery. Criteria for this study included a glaucoma diagnosis of primary OAG (POAG), pigmentary glaucoma, pseudoexfoliation glaucoma, or POAG mixed with another mechanism; an IOP of 16 mm Hg or higher taken, at most, 60 days before surgery (baseline); and a maximum historical IOP of 21 mm Hg or higher. With many patients on maximum tolerated medical therapy, the protocol was designed to allow patients to withdraw from medications due to intolerance or poor compliance provided they had an historically recorded maximum IOP of 21 mm Hg or greater. Patients with more than 2 laser trabeculoplasty procedures or a history of chronic angle closure were excluded. Only 1 eye per patient was eligible.

For efficacy analysis of the canaloplasty procedure, the patients were divided into groups: Group 1 included all

Submitted: December 5, 2008.

Final revision submitted: January 19, 2009.

Accepted: January 20, 2009.

From private practices, Sacramento, California (Lewis), Johnstown, New York (Kearney), Boston, Massachusetts (Shingleton), and Minneapolis, Minnesota (Samuelson), USA; Augen-Tagesklinik Gross Pankow (von Wolff), Gross Pankow, Eye Center Spreebogen and Berlin Eye Research Institute (Tetz), Berlin, and Augen-op-Centrum (Koerber), Koeln, Germany.

Drs. Kearney, Lewis, Samuelson, Shingleton, and Tetz have consulting agreements with iScience Interventional. No author has a financial or proprietary interest in any material or method mentioned.

Supported by iScience Interventional.

Corresponding author: Richard A. Lewis, MD, Grutzmacher & Lewis, 1515 River Park Drive, Suite 100, Sacramento, California 95815, USA. E-mail: rlewiseyemd@yahoo.com.

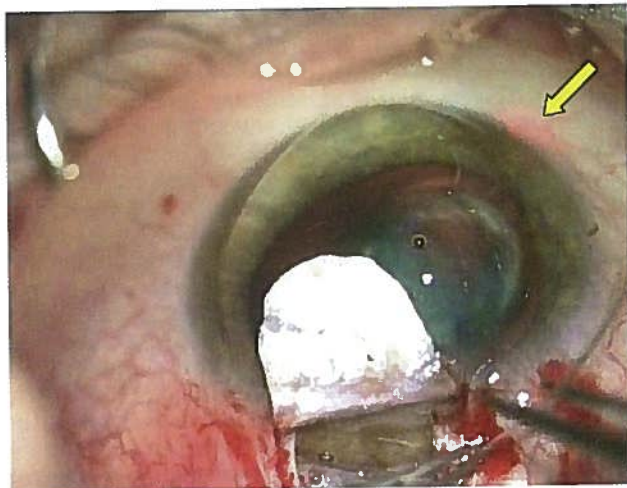


Figure 1. Intraoperative photograph showing the microcatheter being advanced through Schlemm canal. The yellow arrow is pointing at the beacon tip of the microcannula visible through the sclera.

patients meeting the inclusion and exclusion criteria. Group 2 included all patients with successful suture implantation during canaloplasty alone. Group 3 included all patients with successful suture implantation during canaloplasty combined with cataract surgery. Analysis was also performed on subsets of Group 2 based on UBM examination of the trabecular meshwork distension from the intracanalicular suture. Subgroup 2A included all Group 2 patients without observed trabecular meshwork distension and Subgroup 2B, all Group 2 patients with observed trabecular meshwork distension. The primary endpoints included mean IOP and mean number of glaucoma medications at the follow-up visits. The secondary endpoints included surgical and post-surgical complications.

Surgical Technique

Each patient was enrolled to have the canaloplasty procedure using the microcatheter. The microcatheter had a 200 μm diameter shaft with an atraumatic distal tip approximately 250 μm in diameter. The device incorporated an optical fiber to provide an illuminated beacon tip to assist in surgical guidance. The illuminated tip was seen transsclerally during catheterization of Schlemm canal to identify the location of the distal tip of the microcatheter. The microcatheter had a lumen with a proximal Luer lock connector through which an ophthalmic viscosurgical device (OVD) was delivered. The microcatheter was packaged with an OVD injector replacing the standard push syringe used to deliver OVDs to allow more precise injection of microliter volumes.

Surgeons followed traditional viscocanalostomy and deep sclerectomy methods to perform a 2-flap dissection to the canal. A forceps was used to manipulate the microcatheter and place the tip in alignment with the surgically created ostia of the canal. The microcatheter was advanced 12 clock hours within the canal while the surgeon observed the location of the beacon tip through the sclera and injected the OVD (sodium hyaluronate 1.4% [Healon GV]) as the tip was advanced (Figure 1). After catheterization of the entire canal length with the microcatheter and with the distal tip exposed at the surgical cutdown, a 10-0 polypropylene suture was

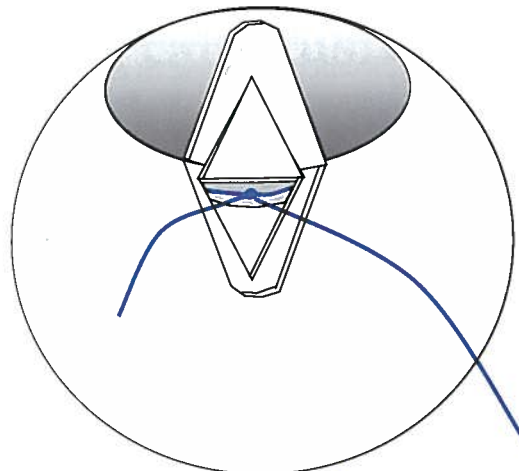


Figure 2. Schematic of circumferential tensioning suture (blue) in Schlemm canal.

tied to the distal tip and the microcatheter withdrawn, pulling the suture into the canal. The suture was cut from the microcatheter and then tied in a loop, encircling the inner wall of the canal using a slip knot. The suture loop was tightened to distend the trabecular meshwork inward, placing the tissues in tension, after which locking knots were added (Figure 2). A descemetic window was formed just before or immediately after catheterization of the canal. The deep flap was excised and the superficial flap was sutured watertight to prevent bleb formation. Additional details of the surgical procedure have been described.²⁴

Ultrasound Biomicroscopy Imaging

High-resolution UBM images of the anterior angle and Schlemm canal were obtained from study eyes preoperatively, intraoperatively, and postoperatively. Of interest were postoperative images collected of all 4 quadrants of the operative eye to assess viscodilation of Schlemm canal, distension of the trabecular meshwork from the tensioning suture, and the size of the surgically created descemetic window.

During the study, evaluation of the acquired UBM images was found to be useful in analyzing for correlation between trabecular meshwork distension and the IOP results. A grading scale was created to represent distension of the trabecular meshwork due to the tensioning suture. The distension was measured by estimating the inscribed angle from the trabecular meshwork displacement using the protractor function of the ultrasound system on representative anterior chamber angle images (Figure 3). The inscribed angle described by an apex at the scleral spur or the iris insertion was used to measure the distension, with resolution to the nearest 0.5 degrees. The angle result was used to categorize distension into a grading range of 0 to 3, with 0 equaling no distension and 3 representing maximum distension (Table 1). The values from multiple quadrants were averaged to provide a mean distension grade for each study eye. The evaluation of the images was performed by trained readers who were masked to patient follow-up data. Each grading was checked

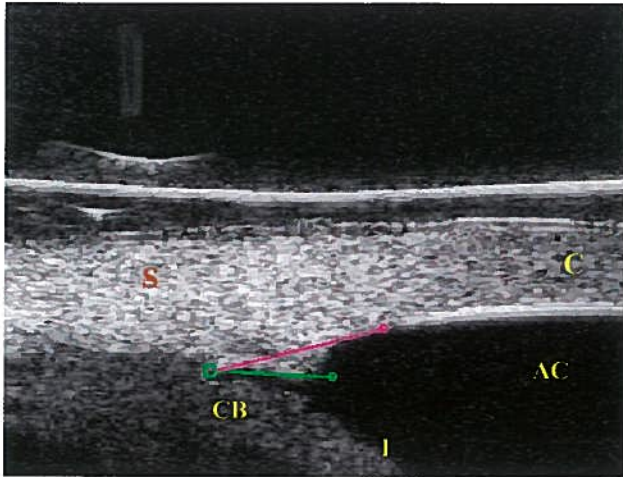


Figure 3. A UBM image of the anterior angle with protractor used for measuring the inscribed angle described by the inward distension of the trabecular meshwork due to the intracanalicular suture. The apex is set at the scleral spur (or the iris insertion point), and the baseline (magenta) is drawn along a line approximating the line of Schlemm canal and the inner surface of the corneo-scleral junction. The second arm (green) is placed along the distended trabecular meshwork (AC = anterior chamber; C = cornea; CB = ciliary body; I = iris; S = sclera).

by a second reader. Grading from the most recent patient imaging session available was used in the data analysis.

Analysis of the 12-month interim results indicated a significant difference in IOP results partitioned by eyes by distension grade. For the 24-month analysis, the results in Group 2 were evaluated using the same criteria for distension grade. The results in the 2 subgroups (Subgroup 2A, mean distension grade <0.5; Subgroup 2B, mean distension grade \geq 0.5) were compared.

Serial UBM images were evaluated from a sampling of eyes to determine whether there were significant changes in trabecular distension over the 2-year study period. Images

of eyes with more than 1 imaging session between the 1-month and 24-month follow-up were reviewed. The images were placed into groups as follows: 1 to 6 months postoperative, 6 to 12 months postoperative, and 12 to 24 months postoperative. The distension grades for these eyes were analyzed for decreases in grade of 0.5 units or more over time.

Visual Acuity

Snellen BCVA was converted to logMAR values for analysis. Visual acuity results in Group 2 were evaluated to assess whether there was a potential loss of vision as a result of the canaloplasty-alone procedure.

Success

The success of the canaloplasty procedure was examined using associative analysis as described in the Advanced Glaucoma Intervention Study (AGIS): 7.¹ In the AGIS 7 associative analysis, eyes with 100% of visits with IOP less than 18 mm Hg had nearly zero change to the mean visual field defect score at long-term follow-up. Using AGIS 7 as a guideline, an associative analysis was prepared for the canaloplasty data. The number of 6-month interval follow-up visits at which the IOPs were below 18 mm Hg was tallied. Patients missing more than 1 visit during the follow-up period were excluded from analysis. Eyes were separated into the 4 analysis groups shown in Table 2. Because the analysis covered 24 months, only four 6-month periods were included.

Statistical Analysis

One-way analysis of variance and the Wilcoxon signed rank test were performed for IOP, glaucoma medication, and visual acuity results at all postoperative time points compared with the values at baseline. Comparison of the means for all pairs of follow-up times was performed using the Tukey-Kramer correction adjusted for multiple comparisons. Individual pair-wise comparison of group means using the Student *t* test was performed for trabecular distension partitioned results from UBM imaging.

RESULTS

Demographics

The study group consisted of 127 patients who met study inclusion and exclusion criteria with consent for

Table 1. Conversion table of angle of trabecular distension to distension grade.

Angle (Degrees)	Distension Grade
0.0-5.0	0.00
5.5-6.5	0.25
7.0-8.0	0.50
8.5-9.5	0.75
10.0-11.0	1.00
11.5-12.5	1.25
13.0-14.0	1.50
14.5-15.5	1.75
16.0-17.0	2.00
17.5-18.5	2.25
19.0-20.0	2.50
20.5-21.5	2.75
22.0+	3.00

Table 2. Associative analysis groupings.

AA Group	AGIS 7: Visits with IOP <18 mm Hg (%)	Canaloplasty: Visits with IOP <18 mm Hg, n (%)
A	100	4 (100)
B	75 to <100	3 (75)
C	50 to <75	2 (50)
D	0 to 50	0 or 1 (<50)

AA = associative analysis; AGIS = Advanced Glaucoma Intervention Study; IOP = intraocular pressure

Table 3. Study group demographics.

Parameter	Value
Enrollees, n	127
Eyes, n	127
Age (y)	
Mean \pm SD	67 \pm 11
Range	37-88
Sex, n (%)	
Female	63 (49.6)
Male	63 (49.6)
Unrecorded	1 (0.8)
Race, n (%)	
White	114 (89.8)
African American or African descent	8 (6.3)
Hispanic	4 (3.1)
Asian	1 (0.8)
Pseudophakic at baseline, n (%)	16 (12.6)
Diagnosis, n (%)	
POAG	113 (89.0)
PXF	8 (6.3)
Mixed (POAG and PXF)	2 (1.6)
Mixed (POAG and acute angle closure)	2 (1.6)
Pigmentary dispersion glaucoma	2 (1.6)
Previous ocular surgery, n (%)	
Laser trabeculoplasty	21 (16.5)
Peripheral laser iridotomy	7 (5.5)
Nd:YAG capsulotomy	1 (0.8)
Successful placement of intracanalicular suture, n (%)	108 (85)
Combined procedure (phacocanaloplasty), n (%)	30 (24)

Nd:YAG = neodymium:YAG; POAG = primary open-angle glaucoma; PXF = pseudoexfoliation glaucoma

long-term follow-up. Group 1 (all included patients) consisted of 127 eyes in 127 patients at baseline and 106 eyes in 106 patients (85%) at 24 months. Of the 21 patients (16.5%) not represented in the 24-month cohort, 6 (4.7%) had confirmed missed visits at 24 months, 4 (3.1%) had early terminations; the 24 month-data for 11 patients (8.7%) had not been collected at the time of manuscript preparation. The 4 early terminations included 1 patient (0.8%) converted to trabeculectomy and 1 patient (0.8%) converted to tube shunt 6 months and 18 months postoperatively, respectively, because of poor IOP control. One patient (0.8%) died after 18 months, and 1 patient (0.8%) withdrew after 18 months for personal reasons.

Table 3 shows the demographics of all patients. The reasons for not achieving successful suture placement in 19 eyes were primarily device and anatomical factors, such as the microcatheter tip entering a collector channel ostium, or other factors that prevented full catheterization of Schlemm canal. No significant adverse events resulting from failure to catheterize the canal were recorded.

Table 4. Postoperative interventions.

Intervention	Number (%)
Cataract surgery	11 (8.6)
Laser goniopuncture	6 (4.7)
Conjunctival suture replacement	5 (3.9)
Nd:YAG capsulotomy	5 (3.9)
Peripheral laser iridotomy	2 (1.6)
Cyclophotocoagulation	1 (0.8)
Iridoplasty	1 (0.8)
Paracentesis	1 (0.8)
Selective laser trabeculoplasty	1 (0.8)
Wound revision	1 (0.8)
Nd:YAG laser to reduce synechias	1 (0.8)

Nd:YAG = neodymium:YAG

Ninety-seven eyes (76%) had canaloplasty alone (Group 2). Thirty eyes (24%) had visually significant cataract and had canaloplasty combined with phacoemulsification and IOL implantation (phacocanaloplasty) (Group 3).

Postoperative Interventions

Table 4 shows the interventions in the 24-month postoperative period. The most frequent intervention was cataract surgery, followed by laser goniopuncture and replacement of a conjunctival suture for surgical site leakage

Procedure Efficacy

Table 5A and Figure 4 show the efficacy results in Group 1. At baseline, 28 (22.0%) eyes were on 3 or more medications at baseline and 6 eyes (4.7%) were not on any medication. At 24 months, 65 eyes (61.3%) were not on medication and 3 eyes (2.8%) were on 3 or more medications. At 24 months, the decrease in the mean IOP from baseline was 32% and the mean reduction in medication use, 74%. All time-point IOP and medication-use results were statistically significant versus baseline values ($P < .001$).

Table 5B and Figure 5 show the efficacy results in Group 2. At baseline, 17 eyes (20.2%) were on 3 or more medications and 2 eyes (2.4%) were not on any medication. At 24 months, 40 eyes (55.5%) were not on any medication and 2 eyes (2.7%) were on 3 or more medications. At 24 months, the decrease in the mean IOP from baseline was 30% and the mean reduction in medication use, 70%. All time-point IOP and medication-use results were statistically significant versus baseline values ($P < .001$).

Table 5C and Figure 6 show the efficacy results in Group 3. At baseline, 6 eyes (25.0%) were on 3 or

Table 5A. Results in Group 1 (all included eyes).

Exam	n	Mean IOP (mm Hg) ± SD (Range)	Mean Medications (n) ± SD (Range)
Baseline	127	23.6 ± 4.8 (16–38)	1.9 ± 0.8 (0–4)
Postoperative			
3 mo	88	15.7 ± 5.3 (7–46)	0.3 ± 0.6 (0–3)
6 mo	83	15.6 ± 4.0 (8–28)	0.3 ± 0.5 (0–2)
12 mo	101	15.4 ± 4.2 (8–30)	0.4 ± 0.7 (0–3)
18 mo	100	16.1 ± 4.1 (7–27)	0.4 ± 0.6 (0–2)
24 mo	106	16.0 ± 4.2 (7–35)	0.5 ± 0.8 (0–3)

more medications and 2 eyes (8.3%) were not on any medication. At 24 months, 17 eyes (85.0%) were not on any medication and no eye was on more than 1 medication. At 24 months, the decrease in the mean IOP from baseline was 42% and the mean reduction in medication use, 88%. All time-point IOP and medication-use results were statistically significant versus baseline values ($P < .001$).

Effect of Suture Tension

Ultrasound images for measurement scoring of the distension grade were obtained in 102 (80%) of 127 patients. Twenty-five patients (20%) did not have an imaging session beyond 1 day postoperatively or had images that were not of sufficient quality to obtain an accurate measurement.

Table 6 shows the IOP and medication results in Subgroup 2A (no discernible tension on UBM) and Subgroup 2B (observed tension on UBM). At baseline, the 2 subgroups had nearly identical IOP and medication use. At 24 months in Subgroup 2A, the decrease in the mean IOP from baseline was 20% and the mean reduction in medication use, 60%. The decreases in Subgroup 2B were 31% and 75%, respectively. At 24 months, the difference in mean IOP between Subgroup 2A and Subgroup 2B means was statistically significant ($P = .018$, Student *t* test) (Figure 7, *top*),

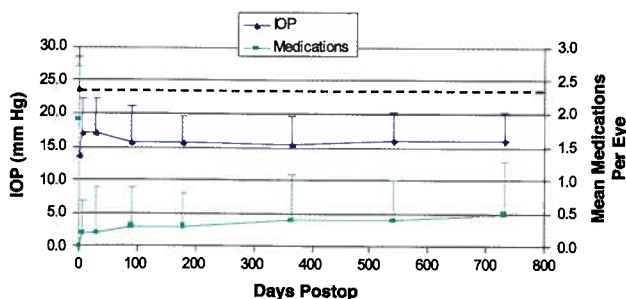


Figure 4. Group 1 efficacy (all included patients) showing mean IOP (\pm SD) and mean medications. The dashed line indicates the baseline IOP of 23.6 mm Hg (IOP = intraocular pressure).

Table 5B. Results in Group 2 (canaloplasty alone).

Exam	n	Mean IOP (mm Hg) ± SD (Range)	Mean Medications (n) ± SD (Range)
Baseline	84	23.2 ± 4.0 (16–38)	2.0 ± 0.8 (0–4)
Postoperative			
3 mo	60	16.5 ± 5.3 (10–46)	0.4 ± 0.7 (0–3)
6 mo	53	16.5 ± 3.9 (8–28)	0.4 ± 0.6 (0–2)
12 mo	67	15.7 ± 3.9 (10–29)	0.5 ± 0.8 (0–3)
18 mo	68	16.2 ± 4.2 (7–27)	0.5 ± 0.6 (0–2)
24 mo	72	16.3 ± 3.7 (8–28)	0.6 ± 0.8 (0–3)

but the difference in medication use was not ($P = .266$, Student *t* test) (Figure 7, *bottom*).

Of the 106 patients in which serial UBM images were evaluated, 24 (23%) had more than 1 graded imaging session during the 24-month follow-up period. Two eyes (8.3%) had a decrease in distension grade of greater than 0.5 units. The eyes were not associated with an elevation in IOP after observation of the decreased distension.

Visual Acuity

Table 7 shows the visual acuity results in Group 2. The mean BCVA in this group at 24 months was not significantly different from that at baseline.

At 24 months, 3 (3%) of 127 eyes in Group 1 had lost 3 or more lines (0.3 logMAR) of BCVA. Of the 3 eyes, 1 (0.8%) had posterior capsule opacification and 1 had a dense nuclear sclerotic cataract; the reason for the visual acuity decrease in the remaining eye was not specified.

Success

Table 8 and Figure 8 show the associative analysis results by group. Twenty (15.7%) of 127 patients did not meet the analysis criteria because of missed visits.

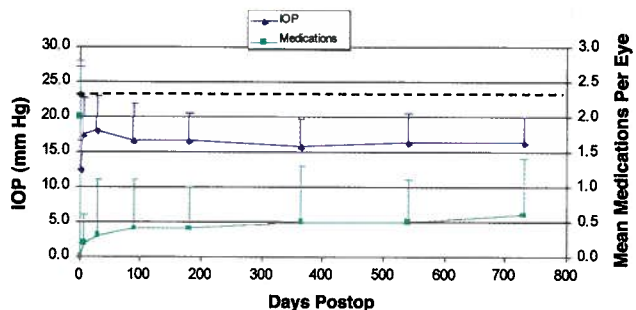


Figure 5. Group 2 efficacy (canaloplasty alone) showing mean IOP (\pm SD) and mean medications. The dashed line indicates the baseline IOP of 23.2 mm Hg (IOP = intraocular pressure).

Table 5C. Results in Group 3 (phacocanaloplasty).

Exam	n	Mean IOP (mm Hg) ± SD (Range)	Mean Medications (n) ± SD (Range)
Baseline	24	23.1 ± 5.5 (16-38)	1.7 ± 1.0 (0-3)
Postoperative			
3 mo	18	13.2 ± 3.7 (7-22)	0.0
6 mo	18	12.8 ± 2.5 (9-20)	0.1 ± 0.2 (0-1)
12 mo	20	13.2 ± 4.0 (8-20)	0.1 ± 0.3 (0-1)
18 mo	15	15.3 ± 4.2 (10-25)	0.1 ± 0.4 (0-1)
24 mo	20	13.4 ± 4.0 (7-22)	0.2 ± 0.4 (0-1)

Surgical and Postsurgical Complications

Overall, the frequency of serious postsurgical complications was low, with 13 adverse events reported in 10 eyes. Table 9 shows all ocular-related surgical and postoperative complications that were reported regardless of severity.

During surgery, there were 3 reported adverse events. The adverse events were classified as mild in severity and probably related to the surgical procedure. One suture extrusion (0.8%) through a partial segment of the trabecular meshwork was reported.

A temporary decrease in the BCVA of 0.6 logMAR occurred in 1 eye at the 1-day follow-up; BCVA returned to the baseline value by the 1-month follow-up visit. The second eye had a reduction in BCVA of 0.22 logMAR at 1 day; BCVA returned to baseline value by the 1-week follow-up visit.

In the early 3-month postoperative period, hyphema was observed in 10 of 127 eyes (7.9%). Cases of gross hyphema reported at the 1-day follow-up resolved at 1 week and 2 weeks postoperatively. Hyphema of 1.0 mm or greater was observed in 8 (6.3%) of 127 eyes at 1 day, 1 (0.9%) of 110 eyes at 1 week, and no

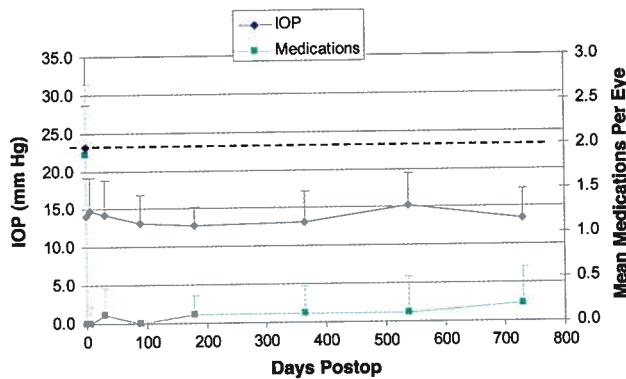


Figure 6. Group 3 efficacy (phacocanaloplasty eyes) showing mean IOP (±SD) and mean medications. The dashed line indicates the baseline IOP of 23.1 mm Hg (IOP = intraocular pressure).

Table 6. Distension-grade partitioned results in Group 2 (canaloplasty alone).

Distension Grade	n	Mean IOP (mm Hg) ± SD (Range)	Mean Medications (n) ± SD (Range)
Less than 0.5			
Baseline	27	22.9 ± 3.6 (16-34)	2.0 ± 0.8 (0-3)
Postoperative			
3 mo	17	18.3 ± 3.7 (13-27)	0.4 ± 0.7 (0-2)
6 mo	18	18.6 ± 3.8 (10-28)	0.6 ± 0.7 (0-2)
12 mo	21	17.7 ± 4.6 (10-29)	1.0 ± 1.0 (0-3)
18 mo	21	17.8 ± 4.6 (7-25)	0.7 ± 0.7 (0-2)
24 mo	21	18.3 ± 4.2 (8-28)	0.8 ± 0.8 (0-3)
0.5 or greater			
Baseline	52	22.9 ± 3.6 (16-38)	2.0 ± 0.8 (1-4)
Postoperative			
3 mo	39	15.9 ± 5.8 (10-46)	0.4 ± 0.7 (0-3)
6 mo	31	15.5 ± 2.8 (8-20)	0.3 ± 0.5 (0-1)
12 mo	44	14.9 ± 3.2 (10-21)	0.3 ± 0.6 (0-2)
18 mo	44	15.4 ± 3.7 (10-27)	0.4 ± 0.6 (0-2)
24 mo	47	15.7 ± 3.1 (9-24)	0.5 ± 0.8 (0-3)

IOP = intraocular pressure

eye at 1 month. Microhyphema (circulating red blood cells without layered blood in the anterior chamber) was noted in 11 eyes at 1 day, 4 eyes at 1 week, and no eye at 1 month.

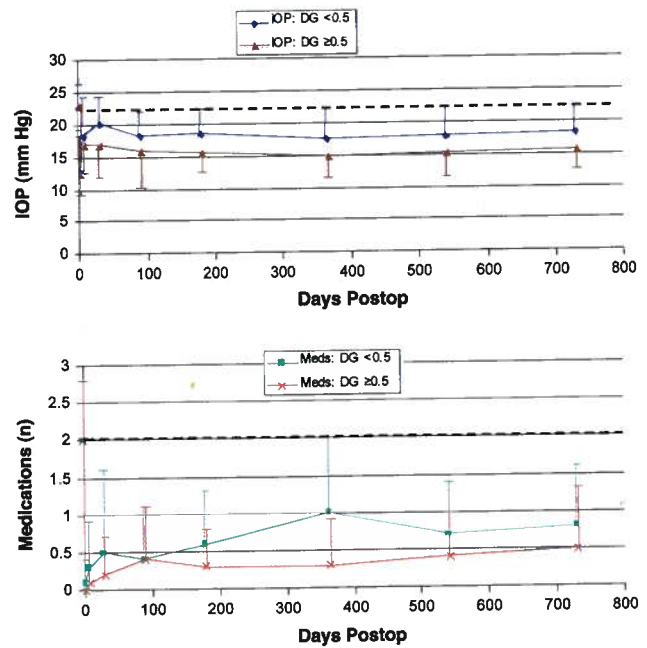


Figure 7. Top: Comparison of mean IOP (± SD) between Subgroup 2A and Subgroup 2B. The dashed line indicates the baseline IOP of 22.9 mm Hg (both groups). Bottom: Comparison of mean medications (± SD) between Subgroup 2A and Subgroup 2B. The dashed line indicates the baseline medication of 2.0 (both groups) (DG = distension grade; IOP = intraocular pressure).

Table 7. Visual acuity results in Group 2 (canaloplasty alone).

Exam	n	Mean LogMAR BCVA \pm SD	P Value*
Baseline	84	0.23 \pm 0.39	—
Postoperative			
3 months	60	0.24 \pm 0.56	.935
6 months	53	0.24 \pm 0.50	.971
12 months	67	0.24 \pm 0.50	.896
18 months	68	0.21 \pm 0.52	.686
24 months	72	0.22 \pm 0.44	.860

BCVA = best corrected visual acuity
*Student *t* test

In the early postoperative period, all cases of IOP elevation (≥ 30 mm Hg) were transient and resolved by the next required study follow-up except in 1 eye. The eye was subsequently treated with glaucoma medications through the 24-month postoperative examination. The wound hemorrhages were located in the corneal incision, subconjunctival space, or trabeculo-descemetetic window and were not associated with elevated IOP. In the eye with hypotony secondary to a break in the trabeculo-descemetetic window during surgery, the hypotony resolved by 1 week; peripheral anterior synechias were noted on the window near the suture location.

Of the eyes with elevated IOP in the late postoperative period, 1 had an IOP of 35 mm Hg at 24 months and was treated with additional medication. One eye with an IOP of 27 mm Hg at 578 days was treated with medications until conversion to trabeculectomy at 651 days. One eye with an IOP of 28 mm Hg at 539 days was treated with medications and revision of the surgical site. The case of suture erosion at the descemetetic window after 1 year was not associated with IOP rise and did not require treatment.

Nonocular-related surgical and postsurgical complications included 9 reported events. These adverse events were not considered to be related to the

procedure or the device. The events included 2 incidents of chest pain, 1 death for unrelated medical reasons, and single incidents of dizziness, dry and numb mouth, hip pain, indigestion, stomach pain, and tinnitus.

DISCUSSION

The canaloplasty procedure intends to increase the flow of aqueous humor from the anterior chamber, through the trabecular meshwork and the descemetetic window, into and around Schlemm canal, and out through the collector channels, thereby reducing IOP. In the 1-year interim clinical study reports,^{24,25} the mean IOP was 16.2 ± 3.5 mm Hg in eyes having canaloplasty alone and 13.7 ± 4.4 mm Hg in eyes having canaloplasty combined with cataract surgery. Medication use dropped to a mean of 0.6 ± 0.9 and 0.2 ± 0.4 , respectively, at 12 months. The 2-year results show nearly equivalent IOP and medication use for canaloplasty alone and canaloplasty combined with cataract surgery. After 2 years, the data indicate continued IOP control.

Although it is difficult to compare results in studies with different patient populations and study methods, the canaloplasty efficacy results are comparable to published reports of trabeculectomy 2 years postoperatively. In general, the Collaborative Initial Glaucoma Treatment Study² found IOP in the range of 14 to 15 mm Hg over the 4 to 5 years of follow-up. Other comparative studies of trabeculectomy^{6,26-31} report a mean IOP after 2 years in the range of 10.1 to 16.9 mm Hg and mean medication use in the range of 0.1 to 1.2 medications. The lowest IOP and medication results were usually associated with the use of adjunctive antimetabolites and careful postoperative management of the eye.^{6,11,14} The associative analysis of the 2-year results indicate that 36% of eyes with canaloplasty alone and 50% of canaloplasty alone eyes with observed trabecular meshwork distension met the criteria for AGIS associative analysis Group A (no mean

Table 8. Associative analysis results at 24 months.

Group in Present Study	n	Number (%)			
		A IOP for 4 Visits <18 mm Hg	B IOP for 3 Visits <18 mm Hg	C IOP for 2 Visits <18 mm Hg	D IOP for <2 Visits <18 mm Hg
1: All included eyes	107	38 (36)	26 (24)	23 (21)	20 (19)
2: Canaloplasty alone	73	26 (36)	14 (19)	18 (25)	15 (21)
3: Phacocanaloplasty	19	9 (47)	6 (32)	2 (11)	2 (11)
2A: Canaloplasty, DG <0.5	23	2 (9)	4 (17)	10 (43)	7 (30)
2B: Canaloplasty, DG \geq 0.5	46	23 (50)	8 (17)	8 (17)	7 (15)

DG = distension grade; IOP = intraocular pressure

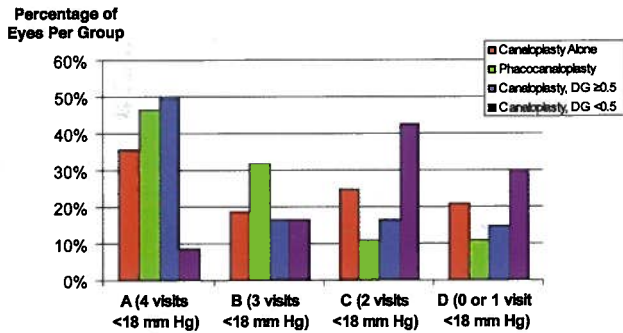


Figure 8. Associative analysis results. Percentage of eyes in Groups 1, 2, 3 and Subgroups 2A and 2B and having a postoperative IOP of less than 18 mm Hg at all visits from 6 months onward (A), at 3 of 4 visits (B), at 2 of 4 visits (C), and at fewer than 2 visits (D) (DG = distension grade).

progression of visual field loss). Although reporting on a different study population, AGIS¹ found that 24% of patients met Group A criteria 2 years postoperatively.

The safety profile of canaloplasty continues to be favorable over that of penetrating surgery such as trabeculectomy. The acute complications 1 year postoperatively²⁴ compare favorably to those of trabeculectomy. The incidence of hypotony after trabeculectomy is reported to be between 4% and 42%.^{6-8,20,28,30} Hyphema as a postoperative complication in trabeculectomy is reported in 8% to 42% of cases.^{5-8,20,28,30} Choroidal detachment has been reported in the range of 1% to 29%.^{20,28,30} In reexamining the adverse event reporting in the study eyes in the acute postoperative period, the complications compare very favorably, with a 0.8% incidence of hypotony, 7.9% incidence of hyphema, and 0% incidence of choroidal detachment and corneal edema. However, 10 eyes (7.9%) had a transient IOP spike of 30 mm Hg or greater during the immediate postoperative period, which in all but 1 case resolved by the next postoperative visit. Also, microhyphema was observed in 11 eyes (8.7%) 1-day postoperatively, most of which resolved by 1 week and in almost all cases, resolved by 1 month.

Although canaloplasty is designed as a blebless procedure, it was uncertain whether there would be other forms of late postoperative complications. To date, the late complications have been infrequent and include 1 case of suture erosion (0.8%) and 3 cases (2.4%) of transient IOP rise. This is in contrast to trabeculectomy, in which late hypotony, bleb encapsulation with loss of IOP control, and endophthalmitis are constant concerns.

The early surgical cases for the investigators were often without observed trabecular meshwork distension on UBM. Suture tensioning and observed distension improved for most investigators with a greater number of enrolled eyes. Eyes with observed

Table 9. Ocular-related and postoperative surgical complications.

Complication	n (%)
Microhyphema (<1.0 mm layered blood)	10 (7.9)
Early elevated IOP (0-3 mo postop)	10 (7.9)
Hyphema (≥1.0 mm layered blood)	8 (6.3)
Blebs at 24 months	4 (3.8)
Late elevated IOP (>3 mo postop)	3 (2.4)
Wound hemorrhage	3 (2.4)
Descemet membrane detachment	2 (1.6)
Gross hyphema	2 (1.6)
Suture extrusion through trabecular meshwork	2 (1.6)
Hypotony	1 (0.8)

IOP = intraocular pressure

trabecular meshwork distension from suture tension had a lower mean IOP than eyes without distension 1 year postoperatively and continued to show a statistically significantly lower IOP and medication use at 2 years. Whether the beneficial effect is derived from a pilocarpine-like effect on the trabecular meshwork,^{32,33} stenting of Schlemm canal,³⁴ or a combination is not clear. However the difference in postoperative IOP between eyes with a tensioning suture and at least some observable trabecular meshwork distension (grade ≥0.5) and eyes with no or little observable tension (grade <0.5) supports a beneficial role of trabecular tension.

One year postoperatively, eyes having combined canaloplasty and posterior chamber IOL implantation had significantly lower IOP and medication use than eyes having canaloplasty alone,^{24,25} indicating an additional effect, possibly due to the IOP-lowering effect of cataract surgery.³⁵⁻³⁹ The efficacy results at 2 years were nearly identical, with a mean IOP of 13.4 mm Hg and 85% of eyes on no medications.

Review of the 2-year postoperative data continues to show a trend of greater success in catheterization of the canal and the placement of the tensioning suture at sites with a greater number of enrolled eyes. The learning curve effect may have had a role in the outcomes; thus, the study results are indicative of a blend of surgeons, many of whom had no experience with nonpenetrating glaucoma surgery before the study. The findings of this 2-year interim analysis indicate that circumferential dilation and tensioning of Schlemm canal is a safe and effective technique to reduce IOP. The study design includes additional follow-up and reporting with more extensive subgroup analysis anticipated during the continuing study.

In conclusion, canaloplasty is a form of nonpenetrating glaucoma surgery that attempts to restore the natural outflow process of the eye without the use of

a subconjunctival bleb. Interim analysis of a prospective clinical study indicated that the surgical procedure appears to effectively lower IOP with few postsurgical complications, with continued control of IOP in patients followed to 2 years. Late complications have been infrequent compared with the incidence with trabeculectomy, which uses a bleb for subconjunctival filtration. The use of a microcatheter in the procedure to access the entire circumference of Schlemm canal facilitates treatment of the trabeculocanalicular outflow system.

APPENDIX

Canaloplasty Clinical Investigators and Centers

Germany: Norbert Koerber, MD, Koeln; Kurt-Dietrich von Wolff, MD, Holger Bull, MD, Augen-Tagesklinik Gross Pankow, Gross Pankow; Manfred Tetz, MD, Eye Center Spreebogen and Berlin Eye Research Institute (BERI), Berlin. **United States:** Michael Field, MD, Bruce Cameron, MD, Northwest Eye Surgeons, Seattle, Washington; Richard Lehrer, MD, Alliance, Ohio; John R. Kearney, MD, Cataract Care Center, Johnstown, New York; Thomas W. Samuelson, MD, Minnesota Eye Consultants, Minneapolis, Minnesota; Garry Condon, MD, Allegheny-Singer Research Institute, Pittsburgh, Pennsylvania; Richard A. Lewis, MD, Grutzmacher & Lewis, Sacramento, California; Marlene Mosler, MD, Rick Wilson, MD, Wills Eye Hospital, Philadelphia, Pennsylvania; Bradford Shingleton, MD, Ophthalmic Consultants of Boston, Boston, Massachusetts; Ronald Fellman, MD, Glaucoma Associates of Texas, Dallas, Texas; Howard Weiss, MD, Washington Eye Physicians and Surgeons, Chevy Chase, Maryland; Alan L. Robin, MD, Johns Hopkins University, Baltimore, Maryland

REFERENCES

- The AGIS Investigators. The Advanced Glaucoma Intervention Study (AGIS): 7. The relationship between control of intraocular pressure and visual field deterioration. *Am J Ophthalmol* 2000; 130:429-440
- Feiner L, Piltz-Seymour JR. Collaborative Initial Glaucoma Treatment Study: a summary of results to date. *Curr Opin Ophthalmol* 2003; 14:106-111
- Jones E, Clarke J, Khaw PT. Recent advances in trabeculectomy technique. *Curr Opin Ophthalmol* 2005; 16:107-113
- Borisuth NSC, Phillips B, Krupin T. The risk profile of glaucoma filtration surgery. *Curr Opin Ophthalmol* 1999; 10:112-116
- Gedde SJ, Herndon LW, Brandt JD, Budenz DL, Feuer WJ, Schiffman JC. Surgical complications in the Tube Versus Trabeculectomy Study during the first year of follow-up; the Tube Versus Trabeculectomy Study Group. *Am J Ophthalmol* 2007; 143:23-31
- Scott IU, Greenfield DS, Schiffman J, Nicolela MT, Rueda JC, Tsai JC, Palmberg PF. Outcomes of primary trabeculectomy with the use of adjunctive mitomycin. *Arch Ophthalmol* 1998; 116:286-291
- Jampel HD, Musch DC, Gillespie BW, Lichter PR, Wright MW, Guire KE. Perioperative complications of trabeculectomy in the Collaborative Initial Glaucoma Treatment Study (CIGTS); the Collaborative Initial Glaucoma Treatment Study Group. *Am J Ophthalmol* 2005; 140:16-22
- Edmunds B, Thompson JR, Salmon JF, Wormald RP. The National Survey of Trabeculectomy. III. Early and late complications. *Eye* 2002; 16:297-303
- Mac I, Soltau JB. Glaucoma-filtering bleb infections. *Curr Opin Ophthalmol* 2003; 14:91-94
- Ophir A. Encapsulated filtering bleb; a selective review-new deductions. *Eye* 1992; 6:348-352
- Bindlish R, Condon GP, Schlosser JD, D'Antonio J, Lauer KB, Lehrer R. Efficacy and safety of mitomycin-C in primary trabeculectomy; five-year follow-up. *Ophthalmology* 2002; 109:1336-1341; discussion by GL Spaeth, C Terzidou, A Bhan, 1341-1342
- Anand N, Arora S, Clowes M. Mitomycin C augmented glaucoma surgery: evolution of filtering bleb avascularity, transconjunctival oozing, and leaks. *Br J Ophthalmol* 2006; 90:175-180
- King AJ, Rotchford AP, Alwitary A, Moodie J. Frequency of bleb manipulations after trabeculectomy surgery. *Br J Ophthalmol* 2007; 91:873-877
- Taube AB, Niemelä P, Alm A. Trabeculectomy with an active postoperative regimen: results and resource utilization. Oxford, In press, *Acta Ophthalmol*, 2009
- Ellingsen BA, Grant WM. Trabeculectomy and sinusotomy in enucleated human eyes. *Invest Ophthalmol* 1972; 11:21-28. Available at: <http://www.iovs.org/cgi/reprint/11/1/21.pdf>. Accessed February 5, 2009
- Johnstone MA, Grant WM. Microsurgery of Schlemm's canal and the human aqueous outflow system. *Am J Ophthalmol* 1973; 76:906-917
- Stegmann R, Pienaar A, Miller D. Viscocanalostomy for open-angle glaucoma in black African patients. *J Cataract Refract Surg* 1999; 25:316-322
- O'Brart DPS, Shiew M, Edmunds B. A randomised prospective study comparing trabeculectomy with viscocanalostomy with adjunctive antimetabolite usage for the management of open angle glaucoma uncontrolled by medical therapy. *Br J Ophthalmol* 2004; 88:1012-1017
- Yalvac IS, Sahin M, Eksioğlu U, Midillioglu IK, Aslan BS, Duman S. Primary viscocanalostomy versus trabeculectomy for primary open-angle glaucoma; three-year prospective randomized clinical trial. *J Cataract Refract Surg* 2004; 30:2050-2057
- Carassa RG, Bettin P, Fiori M, Brancato R. Viscocanalostomy versus trabeculectomy in white adults affected by open-angle glaucoma; a 2-year randomized, controlled trial. *Ophthalmology* 2003; 110:882-887
- Kobayashi H, Kobayashi K, Okinami S. A comparison of the intraocular pressure-lowering effect and safety of viscocanalostomy and trabeculectomy with mitomycin C in bilateral open-angle glaucoma. *Graefes Arch Clin Exp Ophthalmol* 2003; 241:359-366
- Lüke C, Dietlein TS, Jacobi PC, Konen W, Kriegelstein GK. A prospective randomized trial of viscocanalostomy versus trabeculectomy in open-angle glaucoma: a 1-year follow-up study. *J Glaucoma* 2002; 11:294-299
- Cameron B, Field M, Ball S, Kearney J. Circumferential viscodilation of Schlemm's canal with a flexible microcannula during non-penetrating glaucoma surgery. *Digit J Ophthalmol* 2006; 12(1). Available at: <http://www.djo.harvard.edu/site.php?url=/physicians/oa/929>. Accessed February 5, 2009
- Lewis RA, von Wolff K, Tetz M, Koerber N, Kearney JR, Shingleton B, Samuelson TW. Canaloplasty: circumferential viscodilation and tensioning of Schlemm's canal using a flexible microcatheter for the treatment of open-angle glaucoma in adults: interim clinical study analysis. *J Cataract Refract Surg* 2007; 33:1217-1226

25. Shingleton B, Tetz M, Korber N. Circumferential viscodilation and tensioning of Schlemm canal (canaloplasty) with temporal clear corneal phacoemulsification cataract surgery for open-angle glaucoma and visually significant cataract; one-year results. *J Cataract Refract Surg* 2008; 34:433–440
26. ÖnoI M, Aktaş Z, Hasanreisiođlu B. Enhancement of the success rate in trabeculectomy: large-area mitomycin-C application. *Clin Exp Ophthalmol* 2008; 36:316–322
27. Singh RP, Goldberg I, Mohsin M. The efficacy and safety of intraoperative and/or postoperative 5-fluorouracil in trabeculectomy and phacotrabeculectomy. *Clin Exp Ophthalmol* 2001; 29:296–302
28. Murthy SK, Damji KF, Pan Y, Hodge WG. Trabeculectomy and phacotrabeculectomy, with mitomycin-C, show similar two-year target IOP outcomes. *Can J Ophthalmol* 2006; 41:51–59
29. Gilmour DF, Manners TD, Devonport H, Varga Z, Solebo AL, Miles J. Viscocanalostomy versus trabeculectomy for primary open angle glaucoma: 4-year prospective randomized clinical trial. In press, *Eye* 2009
30. Cillino S, Di Pace F, Casuccio A, Cillino G, Lodato G. Deep sclerectomy versus trabeculectomy with low-dosage mitomycin C: four-year follow-up. *Ophthalmologica* 2008; 222:81–87
31. Quaranta L, Hitchings RA, Quaranta CA. Ab-interno goniotrabeculectomy versus mitomycin C trabeculectomy for adult open angle glaucoma; a 2-year randomized clinical trial. *Ophthalmology* 1999; 106:1357–1362
32. Grierson I, Lee WR, Abraham S. Effects of pilocarpine on the morphology of the human outflow apparatus. *Br J Ophthalmol* 1978; 62:302–313. Available at: <http://www.pubmedcentral.nih.gov/picrender.fcgi?artid=1043218&blobtype=pdf>. Accessed February 5, 2009
33. Moses RA, Goldberg I. Pilocarpine-induced movement of the trabecular mesh. *Aust N Z J Ophthalmol* 1986; 14:333–337
34. Cairns JE. Goniospasia: a method designed to relieve canalicular blockade in open-angle glaucoma. *Ann Ophthalmol* 1976; 8:1417–1422
35. Shingleton BJ, Pasternack JJ, Hung JW, O'Donoghue MW. Three and five year changes in intraocular pressures after clear corneal phacoemulsification in open angle glaucoma patients, glaucoma suspects, and normal patients. *J Glaucoma* 2006; 15:494–498
36. Hayashi K, Hayashi H, Nakao F, Hayashi F. Effect of cataract surgery on intraocular pressure control in glaucoma patients. *J Cataract Refract Surg* 2001; 27:1779–1786
37. Mathalone N, Hyams M, Neiman S, Buckman G, Hod Y, Geyer O. Long-term intraocular pressure control after clear corneal phacoemulsification in glaucoma patients. *J Cataract Refract Surg* 2005; 31:479–483
38. Tong JT, Miller KM. Intraocular pressure changes after sutureless phacoemulsification and foldable posterior chamber lens implantation. *J Cataract Refract Surg* 1998; 24:256–262
39. Poley BJ, Lindstrom RL, Samuelson TW. Long-term effects of phacoemulsification with intraocular lens implantation in normotensive and ocular hypertensive eyes. *J Cataract Refract Surg* 2008; 34:735–742



First author:

Richard A. Lewis, MD

*Private practice, Sacramento,
California, USA*

TSP 63849



ELSEVIER

email: reprints@elsevier.com